Asymmetry in Spinal Cord DTI Metrics Correlates with the Loss of Hindlimb Muscle Mass in a Rat Model of Severe Contusion SCI

Celine Baligand, Wootaek Lim, Jonathon Keener, Fan Ye, Ravneet S. Vohra, Arjun Ruhella, Prodip Bose, Glenn A. Walter, Floyd Thompson, Krista H. Vandenborne (UF, Physical Therapy)

Introduction

Spinal cord injury (SCI) induces loss of structural integrity of spinal cord tissue, resulting in locomotor deficit and muscle wasting. Rat models are widely used to study SCI and potential treatments. Most of the current knowledge about the progression of SCI is based on histological studies. To better understand the pathology, it is important to assess the severity of the lesion in conjunction with muscle mass and function. In this work, we used 3D MRI and diffusion tensor imaging (DTI) *ex vivo* to characterize the spinal cord changes following severe contusion SCI in a rat model. In particular, we investigated the use of fractional anisotropy (FA) maps to identify preserved white matter area after injury. We also examined the relationship between preserved FA area and the loss of hindlimb muscle mass induced by contusion SCI, SCI combined with cast immobilization and treadmill training.

Experimental

16-week old female Sprague-Dawley rats underwent spinal cord contusion injury (SCI, n=33). Of them, 11 underwent lower limb cast immobilization for 2 weeks (SCI+IMM) and 11 were subjected to daily locomotor training on a treadmill (SCI+TM). 5 animals were used for control (CTR). Spinal cord tissue was collected after 3 weeks, fixed in para-formaldehyde for a few days, then placed in a 5 mm NMR tube and surrounded with perfluorocarbure for acquisitions. Ex vivo 3D gradient echo images (TR/TE=100/10ms, FOV: 5x5x12 mm^3, resolution: 30x30x100μm^3) and 2D spin echo DTI (TR/TE: 3000/19ms, resolution= 35.16 x 35.16 μm^2, 25 slices, 21 directions) were performed in a Bruker 750MHz magnet. Images were acquired over 1 cm of the length of the cord, including the epicenter. Cross sectional area (CSA) and diffusion parameters were analyzed. FA values from CTR white matter were used to determine an upper threshold and define the preserved spinal cord area following injury: $FA_{damaged\ tissue} < FA_{CTR\ white\ matter} - 2xSD$.

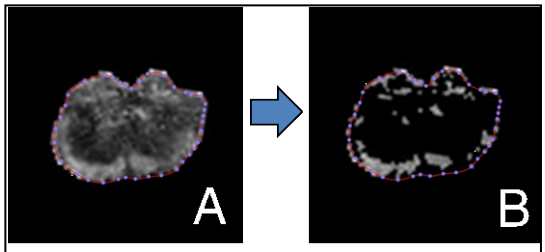

Figure 1: (A) Fractional anisotropy map at the level of the epicenter. (B) Preserved fractional anisotropy map determined by application of a threshold based on control spinal cord values.

Results and Discussion

Figure 1 shows an example of FA maps from the epicenter of an injured cord (A) and the associated preserved FA map (B). Interestingly, preserved FA was mostly located in the ventral medial lateral quadrant of the spinal cord, a region known for its implication in locomotor function. On average, only 11.8% of the epicenter area showed preserved FA values, which represents 12.3% of the whiter matter CSA and 2.7% of the total cord CSA in CTR. This was in agreemant with the preserved white matter area values reported by Basso et al in a similar rat model of SCI and determined by histology (Basso 1996).

Figure 2 shows the relationship (r=0.63) between the triceps surae muscle wet weight left-right asymmetry and the asymmetry measured in the size of the spinal cord at the level of the epicenter (epicenter area).

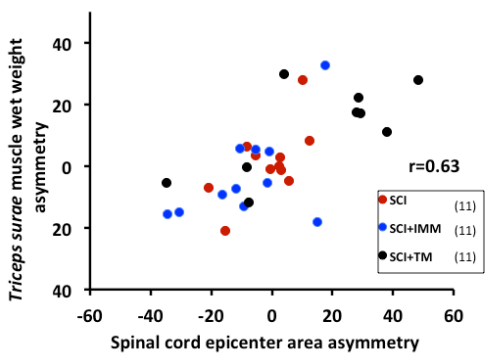

Figure 2: Relationship between hindlimb wet weight asymmetry and spinal cord epicenter area asymmetry

Our results suggest that preserved FA maps have the potential to be used as an indicator of spared tissue in the spinal cord of injured individual, and may be predictive of the changes in muscle mass associated with severe contusion SCI in rats.

Acknowledgements

We acknowledge NIH (PO1 HDO59751) and NHMFL for funding.