17.6T MR Microscopy of Movement Disorders as a Guide for Deep Brain Stimulation

T. Morishita, C. Heon Lee (UF, Neuroscience); M.S. Okun (UF, Neurology and Neurosurgery); S.J. Blackband (UF, Neuroscience); C. Butson (Medical College of Wisconsin, Neurology); V. Vedam-Mai (UF, Neurosurgery); W. Shain (UW, Neurosurgery); K.D. Foote (UF, Neurosurgery)

Introduction

The basal ganglia are a group of deep brain structures that play a pivotal role in select cases of movement disorders and neuropsychiatric disorders. Neuronal circuit theories have been put forth to explain the etiology of many of the symptoms of these diseases [1]. We hypothesized that a higher magnetic field scanner such as a 17.6T MR Microscopy will visualize the details of neuronal circuits in the basal ganglia.

Experimental

Utilizing high-magnetic field MR Microscopy utilizing 17.6 T (750 MHz) MRI scanner (Bruker Bio-spin), we compared different MRI sequences to demonstrate the anatomy of the subthalamic area. The MRI sequences included T1, T2, and diffusion weighted images. In addition, we delineated fiber tractography from 21 directional diffusion tensor imaging scans with 100 μm isotropic resolution.

Results and Discussion

We have scanned five brain hemispheres from Parkinson's disease patients, and three non-pathological brain hemispheres. The T2 weighted image at 25 μm thickness provided the best quality images, and a DTI analysis revealed details of the fiber pathways in the region of interest (Figure 1- below).

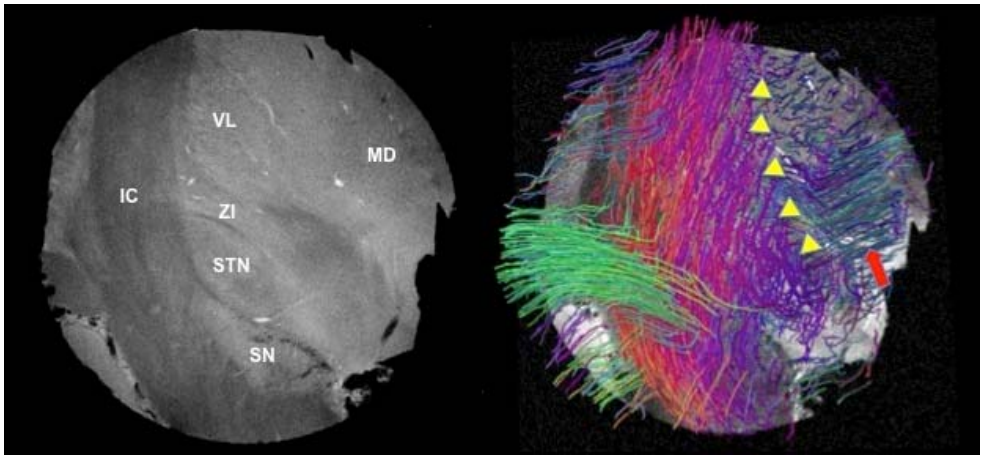

FIGURE 1. Left: T2-weighted image. Right: Fibertractography superimposed on the T2-weighted image. The purple fibers indicated by yellow arrowheads are branched from the cerebral cortex into ventrolateral (VL) nucleus of the thalamus and the subthalamic nucleus (STN). The blue fibers indicated by a red arrow are derived from mediodorsal thalamic nucleus (MD) to form the anterior thalamic peduncle.

Conclusions

17.6 T MR microscopy proved to be a novel technique with tremendous human potential to visualize the anatomical details of the deep brain structures and the associated fiber pathways. In future studies, we will compare images with data collected from excised tissues after deep brain stimulation electrode placement, and determine the ability of MRI to improve the location of said electrodes and evaluate the successfulness of electrode placement as a guide to improving clinical outcome.

Acknowledgements

This study supported by the National High Magnetic Field Laboratory and the NIH (1R01EB012874).

References

[1] Alexander *et al.*, Annual Reviews of Neuroscience **9**, 357-381 (1986)