Characterizing Blood Brain Barrier Breakdown with Status Epilepticus Brain Injury

Sarntinoranont, M. (UF, Mechanical & Aerospace Engineering); Mareci, T.H. (UF, Biochemistry & Molecular Biology); Carney, P.F. (UF, Pediatrics); Magdoom, K.N. (UF, Mechanical & Aerospace Engineering); Delgado, F. (UF, Biochemistry & Molecular Biology); Lonser, R. (Ohio State University, Neurological Surgery)

Introduction

Our objective was to use new engineering and imaging tools to quantify BBB breakdown and better understand the effect of neuropathological changes on extravasation and interstitial transport. Status epilepticus brain injury was chosen as a model for BBB breakdown, which also models human epilepsy well. Electrodes are implanted in the rat brain, then stimulated to generate an episode of self-sustaining status epilepticus. The rats were then imaged after approximately 3 hours.

Experimental

In order to quantify BBB injury, we performed DCE-MRI with a temporal resolution of 30 seconds following tail vein injection of Gd-DTPA-BMA. Prior to DCE scans, quantitative T1 (spin echo saturation recovery with TR = 5, 2.5, 1.25, 0.625 and 0.3125 s, TE = 14.05 ms) and HARDI acquisition (diffusion weighted RARE sequence with low b-value = 80 s/mm2 and high b-value = 800 s/mm2) were performed to measure the structural changes in the rat brain with injury. The spatial resolution for all MR acquisitions was 250 µm x 250 µm x 1000 µm, and they were performed at AMRIS 4.7T. The RARE diffusion and quantitative T1 acquisitions were tested on phantoms (N-tridecane and excised rat head) for protocol development and quality assurance.

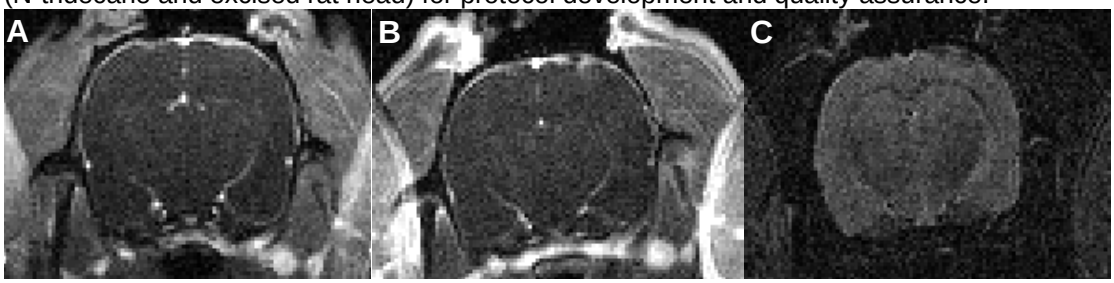

Fig. 1. Structural and BBB changes with status epilepticus; T1-weighted images approximately 3.5 minutes after injecting the contrast agent, Gd-DTPA-BMA in (a) rat #1 and (b) rat #2. (c) T2-weighted image of rat #2. BBB disruption window in status epilepticus was difficult to reproduce consistently as shown by figures 1a and 1b where the BBB was leaky in the hippocampus of rat #1 but not in #2. An alternative model for which BBB disruption model for which blood brain barrier is disrupted is pontine tumor which is currently incurable with very high mortality rate in humans. Even though, it is well known that these tumors are leaky, few studies have looked into the temporal dynamics of leakiness. For this additional animal model, tumor cells (9L glioma) were surgically implanted into the rat pons and grown for several days prior to imaging. DCE-MRI was performed approximately a week after.

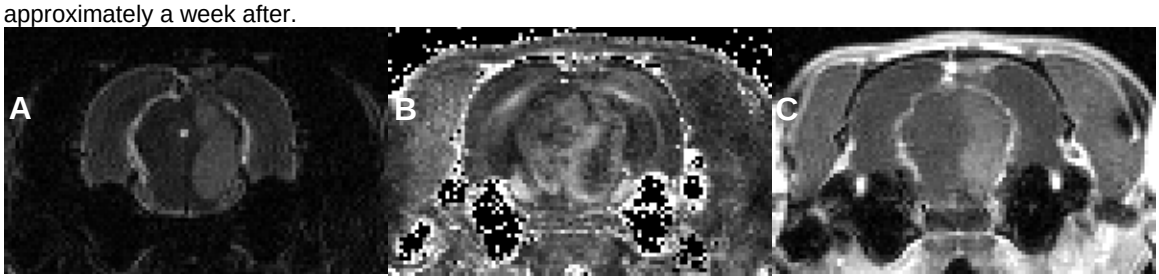

Fig. 2. Structural and BBB changes with pontine glioma; (a) T2-weighted image, (b) fractional anisotropy (FA) image, and (c) T1-weighted image approximately 38 minutes after injecting the contrast agent, Gd-DTPA-BMA.The pontine tumor showed reduced fractional anisotropy (figure 2b) which is expected from the disoriented fibers in the tumor. The BBB breakdown in the tumor was clearly visible in the DCE scans (figure 2c). At this juncture, we have the imaging protocols setup and tested for this study, and we hope to perform additional experiments on more rats for purpose of publication and future grants. This study sustains a continuum of research directed toward development of innovative pharmacologic strategies that will allow treatment in the injured brain.